



Diabetic foot ulcers treatment with silver nanoparticles

Tratamiento de las úlceras del pie diabético con nanopartículas de plata

Almonaci Hernández Cesar Alejandro¹, Cabrera Torres Isis Marion¹, López-Acevedo Rosangela¹, Juárez-Moreno Karla Oyuki^{2,3}, Castañeda-Juárez Martin E.⁴, Almanza-Reyes Horacio⁵, Pestryakov Alexey⁶, Bogdanchikova Nina²

¹Integral and Advance Clinic, Ensenada, Baja California, México.

²Center of Nanoscience and Nanotechnology, National Autonomous University of Mexico. Km107 Carretera Tijuana-Ensenada, Ensenada, Baja California, México.

³CONACYT Research Fellow at Center of Nanoscience and Nanotechnology, National Autonomous University of Mexico. Ensenada, Baja California, México.

⁴School of Medicine. National Autonomous University of Mexico, Ensenada, Baja California, México

⁵School of Medicine and Psychology, Campus Tijuana. Autonomous University of Baja California, Tijuana, Baja California, México.

⁶Tomsk Polytechnic University, Tomsk, Russia.

Corresponding author: Nina Bogdanchikova, Center of Nanoscience and Nanotechnology, National Autonomous University of Mexico. Km107 Carretera Tijuana-Ensenada, Baja California, México. E-mail: nina@cnyu.unam.mx. ORCID: 0000-0003-0929-3535.

Recibido: 01 de Julio del 2018 **Aceptado:** 12 de Diciembre del 2018 **Publicado:** 20 de Enero del 2019

Resumen. - *Las úlceras del pie diabético son altamente susceptibles a infecciones microbianas y son la principal causa de hospitalización y amputación de extremidades inferiores en pacientes diabéticos. Debido a sus propiedades antimicrobianas y anti-inflamatorias, las nanopartículas de plata (AgNPs) son el nanomaterial más utilizado en biomedicina. En este trabajo presentamos el uso de AgNPs para el tratamiento de úlceras de pie diabético grado II de la clasificación de Wagner. Además del tratamiento con antibióticos convencionales, las úlceras fueron tratadas mediante la administración tópica de AgNPs a una concentración de 1.2 mg/mL de plata metálica. Los resultados obtenidos, revelan una mejora significativa en la evolución de las úlceras, en donde los bordes de la lesión se acercaron de manera efectiva, observándose tejido de granulación, disminución del edema y placas de fibrina. Estos resultados constituyen la base para nuevos estudios sobre el uso de AgNPs para el tratamiento de úlceras crónicas de diferentes orígenes.*

Palabras clave: Úlceras del Pie Diabético; Diabetes Mellitus; Nanopartículas de Plata; Nanomedicina; Úlceras Crónicas.

Abstract. - *Diabetic foot ulcers are highly susceptible to microbial infections and are the leading cause of lower limb hospitalization and amputation in diabetic patients. Due to their antimicrobial and anti-inflammatory properties, silver nanoparticles (AgNPs) are the most widely used nanomaterial in biomedicine. Herein, we present the usage of AgNPs for the treatment of diabetic foot ulcers with a stage II in Wagner classification. In addition to conventional antibiotic treatment, the ulcers were treated with topical administration of AgNPs at a concentration of 1.2 mg/ml of metallic silver. The results showed a significant improvement in the evolution of the ulcers, where the edges of the lesion were effectively approached, granulation tissue being observed, edema decreased and fibrin plaques. These results form the basis for further studies on the use of AgNPs for the treatment of chronic ulcers of different origins.*

Keywords: Diabetic Foot Ulcers; Diabetes Mellitus; Silver Nanoparticles; Nanomedicine; Chronic Ulcers.



1. Introduction

Diabetes mellitus (DM) is the second major cause of death in Mexico [1]. Twenty-five percentage of patients with DM developed complications of lower limbs known as diabetic foot ulcers (DFU) [2]. These types of ulcers are characterized by poly-microbial infection, ulceration and destruction of the deepest tissues of lower limbs, associated with neurologic alterations and diverse degrees of peripheral vascular disease [3]. Therefore, DFU are the main cause of hospitalization and lower limbs amputation [3][5].

The assessment of a patient with DFU starts with wound cleaning, debridement and antibiotic schedule treatment [7]. If no evidence of healing is shown and complications of the DFU such as gangrene and osteomyelitis are observed, then a surgical management is recommended involving the amputation of the lower limb [8].

Infection of DFU with multi-drug resistance (MDR) microorganisms may increase the time of wound healing, hospitalization, treatment costs and patient mortality [9]. Therefore, due to its well-known antimicrobial properties, silver has been extensively used in a wide variety of products on the market to treat bacterial infection and to prevent wound sepsis [10]. However, all of these formulations have limitations concerning the need for a high-frequency application and the inactivation of silver. In this sense, nanotechnology has generating new applications for biomedicine through the synthesis of nanomaterials [11]. One of the most used nanomaterial in medical products is silver nanoparticles (AgNPs).

Owning to their antibacterial and anti-inflammatory properties [12, 13], AgNPs have been intensively applied for wound healing

[13] but scarcely studied in vitro and in animal models for the treatment of diabetic ulcers, this may be due to the high risk of limb amputation in patients [14, 15]. However, the use of AgNPs to heal DFU in DM patients has never been studied before our group began to investigate it [16]. Taking this in consideration, the aim of this study is to investigate the potential use of AgNPs for the treatment of DFU in patients.

2. Methodology

2.1 Silver nanoparticle formulation

After comparison with different AgNPs commercially available, we concluded that only Argovit preparation resulted to have multiple certificates for their usage in veterinary and human applications [17]. Argovit (Scientific and Production Center Vector-Vita, Novosibirsk, Russia) is a preparation of highly dispersed AgNPs with an overall concentration of 200 mg/mL (20%) of polyvinylpyrrolidone-coated AgNPs in water. The content of metallic silver in Argovit preparation is 12 mg/ml, stabilized with 188 mg/ml of polyvinylpyrrolidone (PVP). AgNPs dilutions were calculated according to metallic silver content in Argovit preparation. Solutions of AgNPs were prepared with distilled and sterile water and were kept at 4°C in darkness.

2.2 Silver nanoparticle characterization

Size distribution and morphology of AgNPs were determined on the basis of the results obtained by high-resolution transmission electron microscopy (HRTEM) using a JEOL-JEM-2010 microscope. Hydrodynamic radius and Zeta potential were measured by dynamic light scattering (DLS) (Malvern Instruments Zetasizer Nano NS model DTS 1060, UK)



equipped with a green laser operating at $\lambda = 532$ nm at 25 °C. AgNPs were characterized by UV-Vis spectroscopy in the range of 200 to 900 nm using a Cary 60 UV-Vis spectrophotometer (Agilent Technologies, Santa Clara, CA, USA). Further characterization of lyophilized Argovit was performed with Fourier transform infrared spectroscopy-attenuated total reflectance (FTIR-ATR) analysis in the range of 400 to 4000 cm^{-1} with a resolution of 2 cm^{-1} on a universal diamond ATR top plate accessory (Perkin Elmer, USA); the sample spectrum was compared with that of standard solid PVP (Mw 100kD).

2.3 Method of topical AgNPs application

The novel method for topical administration of AgNPs for DFU treatment was developed by Med. César Alejandro Almonaci Hernández. The researching protocol for this study was approved by the Bioethic Committee of the General Hospital of Tijuana, Baja California Mexico. All patients included in this study signed an informed consent letter.

2.4 Clinical cases

Here it is presented two clinical cases of diabetic patients with a DFU of stage II according to Wagner classification. The first patient is a 46-years old male with a 10 years' evolution of controlled type-2 diabetes. He presented a non-improved plantar ulcer in the right forefoot at metatarsus level without vascular involvement. DFU area is approximately 4 cm. After surgical cleaning protocol and treatment with conventional antibiotics, the surface area of the wound did not diminished and no significant improvement was noticed. Second patient is a 40- years old male with 8 years' evolution of insulin- controlled type 2-diabetes. Patient referred the wound appear after 2 weeks of been subjected to an Achilles tendon surgery.

He presented a non- improved asymmetric ulcer in the back face of right leg with 5 cm in length. DFU presents a red-brown color with yellow patches of dispersed granular tissue. Although infection was not detected, wound could not be cured after almost 8 months. After surgical cleaning protocol and treatment with conventional antibiotics, the surface area of the wound did not diminished and no significant improvement was noticed. Therefore patient was included in this study.

2.5 AgNPs treatment of foot ulcer in diabetic patients

The treatment of DFU with AgNPs, started after the patient signed an informed consent letter given his approval to be included in the protocol.

Afterwards, a complete exploration of the wound area, debridement when necessary and cleaning with surgical soap solution. Was performed. Then topical administration of AgNPs solution (with a metallic silver concentration of 1.2 mg/ml) was done firstly, and this treatment was repeated every 24 h for 12 days. The amount of metallic silver to be applied in the injury was calculated on the basis of the content of metallic silver present in the AgNPs solution Argovit, as mentioned in section 2.1.

To record the evolution of the wound healing process, photographs were taken before and after the treatment with AgNPs.

3. Results

3.1. Silver nanoparticle characterization

Our group has recently reported physicochemical characteristic of AgNps [18]. In summary, AgNPs are spheroidal in morphology, the size distribution goes from 1 to 90 nm with an average size of 35 nm, and

their hydrodynamic radio considering both the PVP covering and the metallic silver nanoparticle is 70 nm. Zeta potential of AgNPs is -15 mV and their plasmon absorbance is found at 420 nm wavelength. A TEM micrograph of the AgNPs used in this study is shown in figure 1.

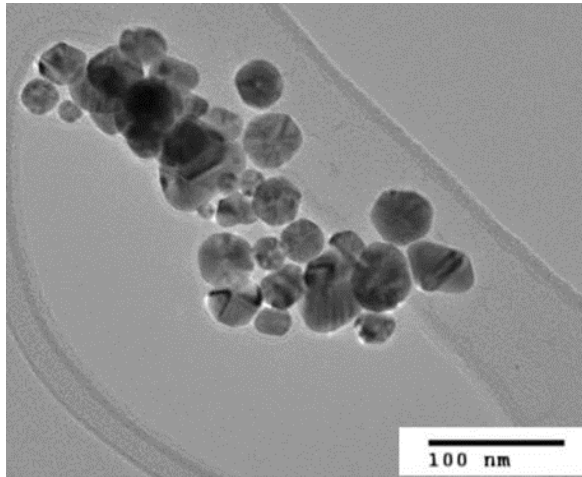


Figure 1. TEM image of AgNPs showing their spheroidal morphology and size.

3.2 Evolution of diabetic foot ulcer healing

The evolution of the wound healing process of DFU treated with AgNPs was documented by photography. In figure 2 it is observed the chronological evolution of DFU from two the patients. In figure 2A it is shown the initial appearance of a Wagner II ulcer after the debridement process. The DFU is located in the forefoot and imposed on the metatarsal region of the right foot. The extended area of the DFU is approximately of 3 cm x 4 cm and 0.4 cm deep, with irregular contours and hyperkeratosis active edges. After 8 days of treatment with AgNPs solution, there was an improvement of the ulcer with reduction of edema. It exhibits a red coloration without signs of infection. The outer contour of the ulcer shows a progressive decrease of granular tissue and fibrin plaques at the center of the ulcer. The evolution of the healing process after 12 days of topical administration of AgNPs solution, in this picture, a progressive

diminishment of the lesion extent is noticeable. An evident improvement of the coping is observed along the edges of the DFU while granulation tissue is depicted at the center of the ulcer. Indeed, the central zone of the ulcer shows a diminishment of its diameter with an evident improvement in the pigmentation that confirms the imminent re-epithelialization process with active edges that favoring closure of the injury.

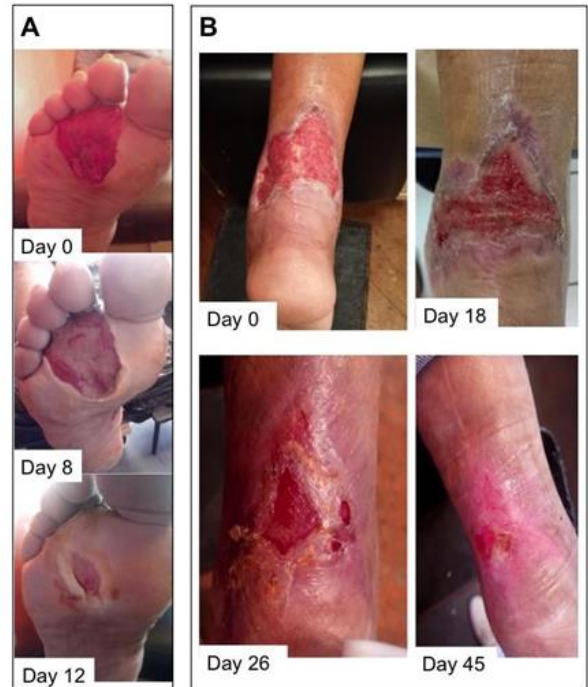

Figure 2. Chronological evolution of the lesion of diabetic foot ulcers classified as Wagner grade II, treated with topical administration of AgNPs. DFU from (A) 46 years-old male patient with type-2 diabetes and (B) 40 years-old male patient with type-2 diabetes. In both figures (A and B) initial appearance of the ulcer is shown and the evolution of the DFU after several days of treatment with AgNPs solution.

Figure 2B depicts the initial Wagner II ulcer located in the back of the right leg forefoot. DFU has an extension of 5 cm approximately with asymmetric edges. After 18 days of treatment with AgNPs solution, there was 50% of improvement in healing process of the ulcer. DFU exhibits coping of active edges through re-epithelialization and no signs of infection were observed. The contours of DFU



show a progressive closure. The presence of granular tissue, red color and well-moisturized skin was observed. On day 26, the edges of the wound were active and allowed the coping of the borders of the lesion reducing its area. Granular tissue and red color in the middle of the ulcer were observed. Finally, after 45 days of treatment with AgNPs, DFU has attempted the closure in 95%. Granular tissue is observed along 5 cm. No edema, infection or flush was detected. Coping of wound edges was successful and reached the closure of the ulcer.

4. Conclusions

Thus, we present herein two clinical cases of successful treatment of diabetic foot ulcers of II degree of Wagner classification with AgNPs topically administered into the wound. Daily administration of AgNPs solution with metallic silver concentration of 1.2 mg/mL causes an improvement of the wound healing in less than 2 months. To the best of our knowledge, successful treatment of diabetic ulcers with AgNPs, discovered by our group, for the first time was described in our previous work [16]. This work is the second work of series of publications of our group dedicated to clinical cases of rapid wound healing of diabetic foot ulcers treated with AgNPs. It has been extensively reported the use of AgNPs for healing a wide spectrum of wounds including different types of ulcers. However, its study for the successful treatment of diabetic foot ulcers in patients has never been explored before our two publications (our previous article [16] and this work). Therefore, the results of our series of works will permit to include diabetic ulcers type, characterized by high extremity amputation risk, to this spectrum.

5. Acknowledgements

The authors wish to thank the funding through the International Network of

Bionanotechnology with impact in Biomedicine, Food and Biosafety (CONACYT project No. 279889) and to the CONACYT project No. 269071. This work was also supported by DGAPA PAPIIT-UNAM IT200114 project. Authors wish to thank Dr. Oxana Martyniuk and Sr. Francisco Ruiz Medina for their technical support. Authors acknowledge the medical support given by Carmen Enriques Enriques, Willfred Cárdenas Acosta, Michel Natay Peraza Perales, Alejandra Rembao Hernández and Nora Inés Carricury Chequer. We are grateful to Dr. Leonel Cota (CNyN-UNAM) for the studentships given through the CONACYT-SNI 3 researcher fund. Argovit AgNPs were kindly donated by Professor Dr. Vasily Burmistrov from the Scientific and Production Center Vector-Vita (Russia).

Referencias

- [1] J. P. Hernández-Ávila, Mauricio Gutiérrez and N. Reynoso-Noverón, "Diabetes mellitus en México. El estado de la epidemia," *Salud Pública de México*, vol. 55, no. 2, p. 129-S136., 2013. <https://doi.org/10.21149/spm.v55s2.5108>
- [2] S. Lopez-Antuñano and F. J. López- Antuñano, "Disponible en: http://www.redalyc.org/articulo.oa?id=1064_0310," *Salud Publica Mex.*, vol. 40, no. 4, pp. 281-292, 1998. <https://doi.org/10.1590/S0036-36341998000300010>
- [3] M. S. Bader, "Diabetic foot infection.," *Am. Fam. Physician*, vol. 78, no. 1, pp. 71-9, 2008. <https://www.aafp.org/afp/2008/0701/p71.html>
- [4] E. J. Boyko, J. H. Ahroni, V. Cohen, K. M. Nelson, and P. J. Heagerty, "Prediction of diabetic foot ulcer occurrence using commonly available clinical information: the Seattle Diabetic Foot Study.," *Diabetes Care*, vol. 29, no. 6, pp. 1202-7, Jun. 2006. <https://doi.org/10.2337/dc05-2031>
- [5] J. Apelqvist and J. Larsson, "What is the most effective way to reduce incidence of amputation in the diabetic foot?," *Diabetes. Metab. Res. Rev.*, vol. 16 Suppl 1, pp. S75- 83, Jan. [https://doi.org/10.1002/1520-7560\(200009/10\)16:1+<::AID-DMRR139>3.0.CO;2-8](https://doi.org/10.1002/1520-7560(200009/10)16:1+<::AID-DMRR139>3.0.CO;2-8)
- [6] I. Uckay, K. Gariani, Z. Pataky, and B. A. Lipsky, "Diabetic foot infections: State-of- the-art," *Diabetes, Obes.*



Metab., vol. 16, no. 4, pp. 305-316, 2014.
<https://doi.org/10.1111/dom.12190>

[7] W. J. Jeffcoate and K. G. Harding, "Diabetic foot ulcers," *Lancet*, vol. 361, no. 9368, pp. 1545-1551, May 2003.
[https://doi.org/10.1016/S0140-6736\(03\)13169-8](https://doi.org/10.1016/S0140-6736(03)13169-8)

[8] T. J. Boffeli, "Partial Foot Amputations for Salvage of the Diabetic Lower Extremity," *Clin. Pod. Med. Surg.*, vol. 31, pp. 103-126, 2014.
<https://doi.org/10.1016/j.cpm.2013.09.005>

[9] D. D. A. Martinez-Gomez, C. Ramirez- Almagro, A. Campillo-Soto, G. Morales- Cuenca, J. Pagan-Ortiz, and J. L. Aguayo- Albasini, "Infecciones del pie diabético. Prevalencia de los distintos microorganismos y sensibilidad a los antimicrobianos," *Enferm. Infecc. Microbiol. Clin.*, vol. 27, no. 6, pp. 317-321, 2009.
<https://doi.org/10.1016/j.eimc.2008.07.004>

[10] B. S. Atiyeh, M. Costagliola, S. N. Hayek, and S. A. Dibo, "Effect of silver on burn wound infection control and healing: Review of the literature," *Burns*, vol. 33, no. 2, pp. 139-148, 2007. <https://doi.org/10.1016/j.burns.2006.06.010>

[11] S. Krol, R. Ellis-Behnke, and P. Marchetti, "Nanomedicine for treatment of diabetes in an aging population: State-of-the-art and future developments," *Maturitas*, vol. 73, no. 1, pp. 61-67, 2012.
<https://doi.org/10.1016/j.maturitas.2011.12.004>

[12] H. H. Lara, N. V. Ayala-Núñez, L. del C. Ixtepan Turrent, and C. Rodríguez Padilla, "Bactericidal effect of silver nanoparticles against multidrug-resistant bacteria," *World J. Microbiol. Biotechnol.*, vol. 26, no. 4, pp. 615-621, Oct. 2009. <https://doi.org/10.1007/s11274-009-0211-3>

[13] T. Gunasekaran, T. Nigusse, and M. D. Dhanaraju, "Silver nanoparticles as real topical bullets for wound healing," *Journal of the American College of Clinical*

Wound Specialists, vol. 3, no. 4. pp. 82-96, Dec- 2011.
<https://doi.org/10.1016/j.jcws.2012.05.001>

[14] B. S. Anisha, R. Biswas, K. P. Chennazhi, and R. Jayakumar, "Chitosan-hyaluronic acid/nano silver composite sponges for drug resistant bacteria infected diabetic wounds," *Int. J. Biol. Macromol.*, vol. 62, pp. 310-320, Nov. 2013.
<https://doi.org/10.1016/j.ijbiomac.2013.09.011>

[15] J. Tian, K. K. Y. Wong, C. M. Ho, C. N. Lok, W. Y. Yu, C. M. Che, J. F. Chiu, and P. K. H. Tam, "Topical delivery of silver nanoparticles promotes wound healing," *ChemMedChem*, vol. 2, no. 1, pp. 129-136, Jan. 2007.
<https://doi.org/10.1002/cmdc.200600171>

[16] C. A Almonaci H., K. Juárez-Moreno, M. E. Castañeda-Juárez, H. Almanza-Reyes, A. Pestryakov and N. Bogdanchikova "Silver nanoparticles for the rapid healing of diabetic foot ulcers.", *International Journal of Medical Nano Research*, vol. 4, no 1, pp. 1-6, 2017.
<https://doi.org/10.23937/2378-3664/1410019>

[17] B. Borrego, G. Lorenzo, J. D. Mota-Morales, H. Almanza-Reyes, F. Mateos, E. López-Gil, N. de la Losa, V. A. Burmistrov, A. N. Pestryakov, A. Brun, and N. Bogdanchikova, "Potential application of silver nanoparticles to control the infectivity of rift valley fever virus in vitro and in vivo.," *Nanomedicine*, vol. 12, no. 5, pp. 1185-1192, Mar. 2016.
<https://doi.org/10.1016/j.nano.2016.01.021>

[18] K. Juarez-Moreno, E. B. Gonzalez, N. Girón-Vazquez, A. Chávez, J. D. M. Morales, L. L. Perez-Mozqueda, M. R. Garcia-Garcia, A. Pestryakov, and N. Bogdanchikova, "Comparison of cytotoxicity and genotoxicity effects of silver nanoparticles on human cervix and breast cancer cell lines," *Hum. Exp. Toxicol.*, vol. 36, no. 9, pp. 931-948, 2016.
<https://doi.org/10.1177/0960327116675206>



Este texto está protegido por una licencia [Creative Commons 4.0](https://creativecommons.org/licenses/by/4.0/)

Usted es libre para Compartir —copiar y redistribuir el material en cualquier medio o formato— y Adaptar el documento —remezclar, transformar y crear a partir del material— para cualquier propósito, incluso para fines comerciales, siempre que cumpla la condición de:

Atribución: Usted debe dar crédito a la obra original de manera adecuada, proporcionar un enlace a la licencia, e indicar si se han realizado cambios. Puede hacerlo en cualquier forma razonable, pero no de forma tal que sugiera que tiene el apoyo del licenciante o lo recibe por el uso que hace de la obra.

[Resumen de licencia](#) - [Texto completo de la licencia](#)